

Cerebellar Cognitive Affective Syndrome

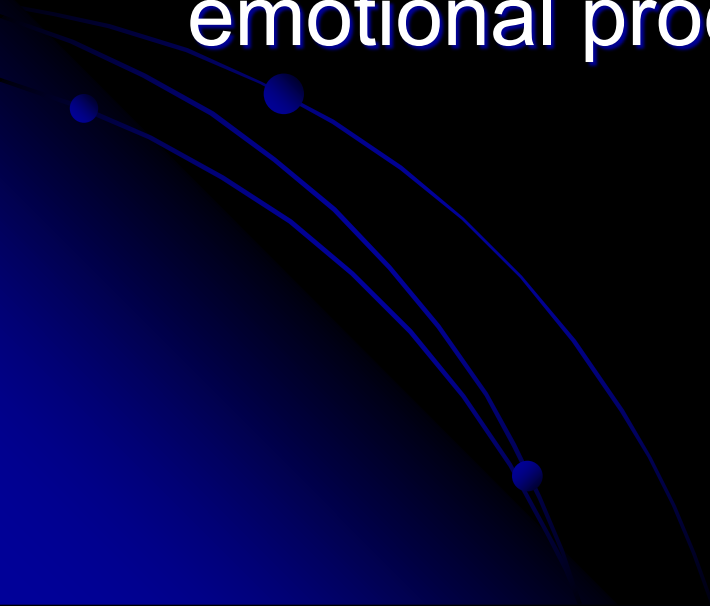Expanding Our Thinking About the
Cerebellum

Anita S. Blair, Psy.D.




Goals for Listening


- 1) New or enhanced appreciation for the roles the cerebellum plays in cognition and emotional processing




2) Review of neuropsychological case findings in cerebellar dysfunction



3) Insights into the psychological impact for patients and families in cerebellar disease



4) Discussion of potential treatments



Many Thanks to....

Jeremy Schmahmann, MD

Massachusetts General Hospital/Harvard

J. of Neuropsychiatry Clinical Neurosci 16:3;Summer 04

Brain 1998

Robin Hurley, MD

Hefner VA Medical Center

Daniel Kaufer, MD


University of North Carolina at Chapel Hill

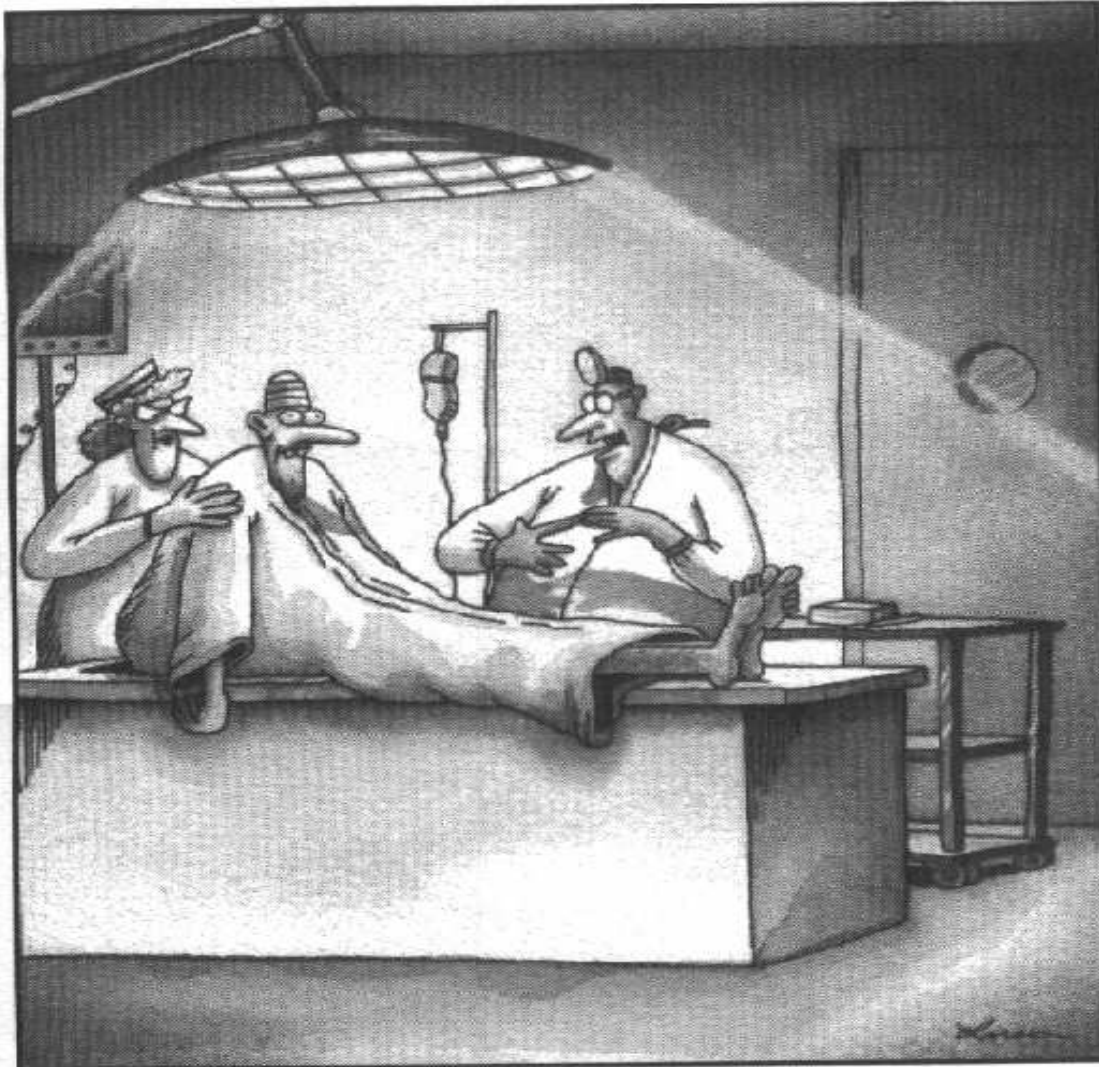
Hal Blumenfeld, MD, PhD

Neuroanatomy Through Clinical Cases

Wikipedia ☺


And before we get too serious,
too excited about what we
know...



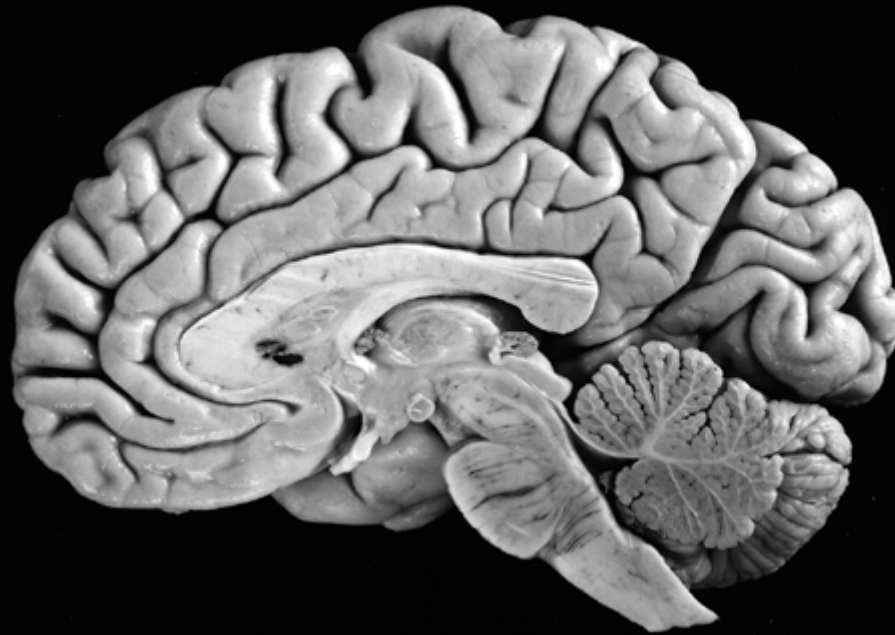

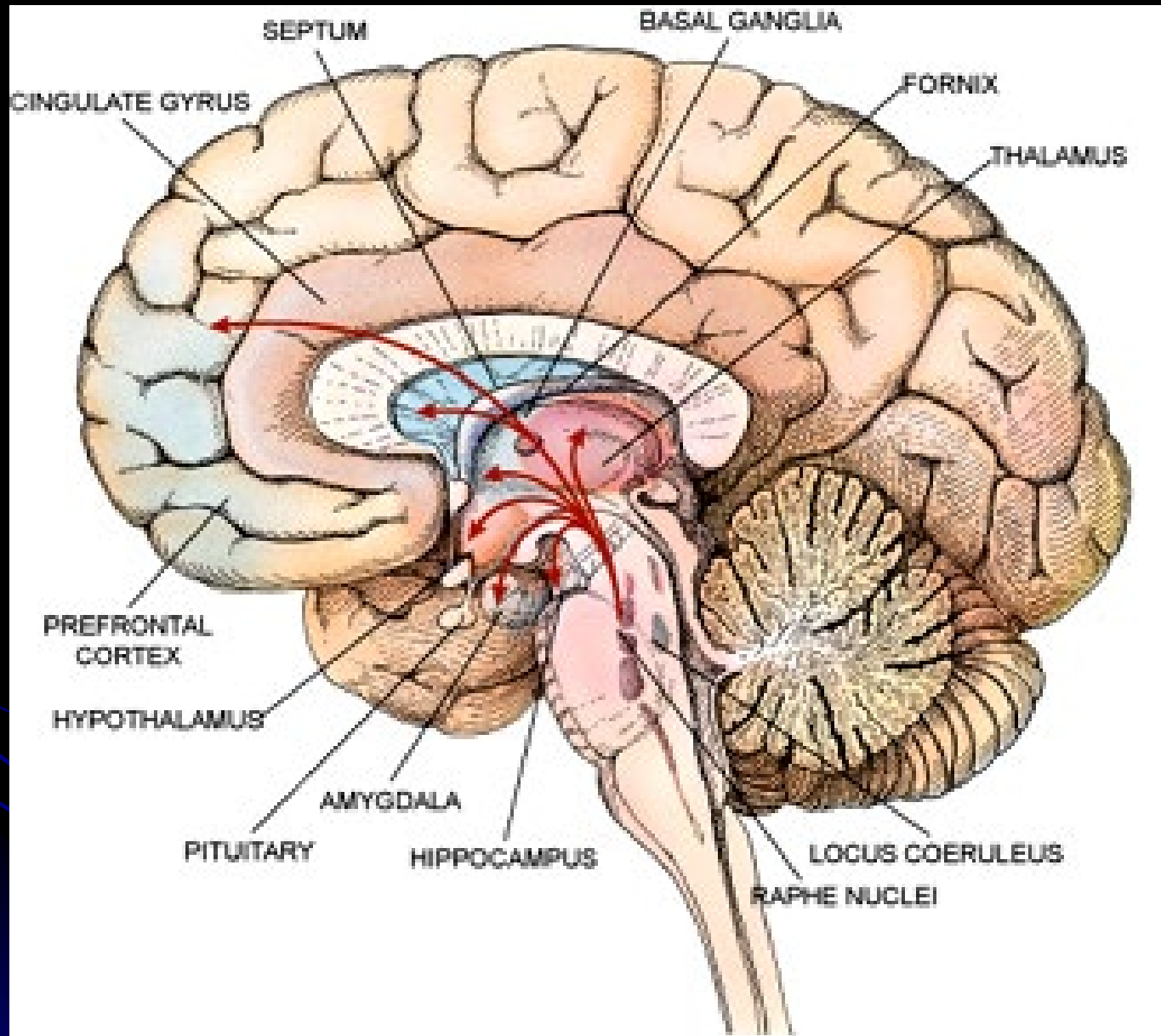
“OK, Mr. Dittmars, remember: That brain is only a temporary, so don't think too hard with it.”

Lets Unveil the Cerebellum

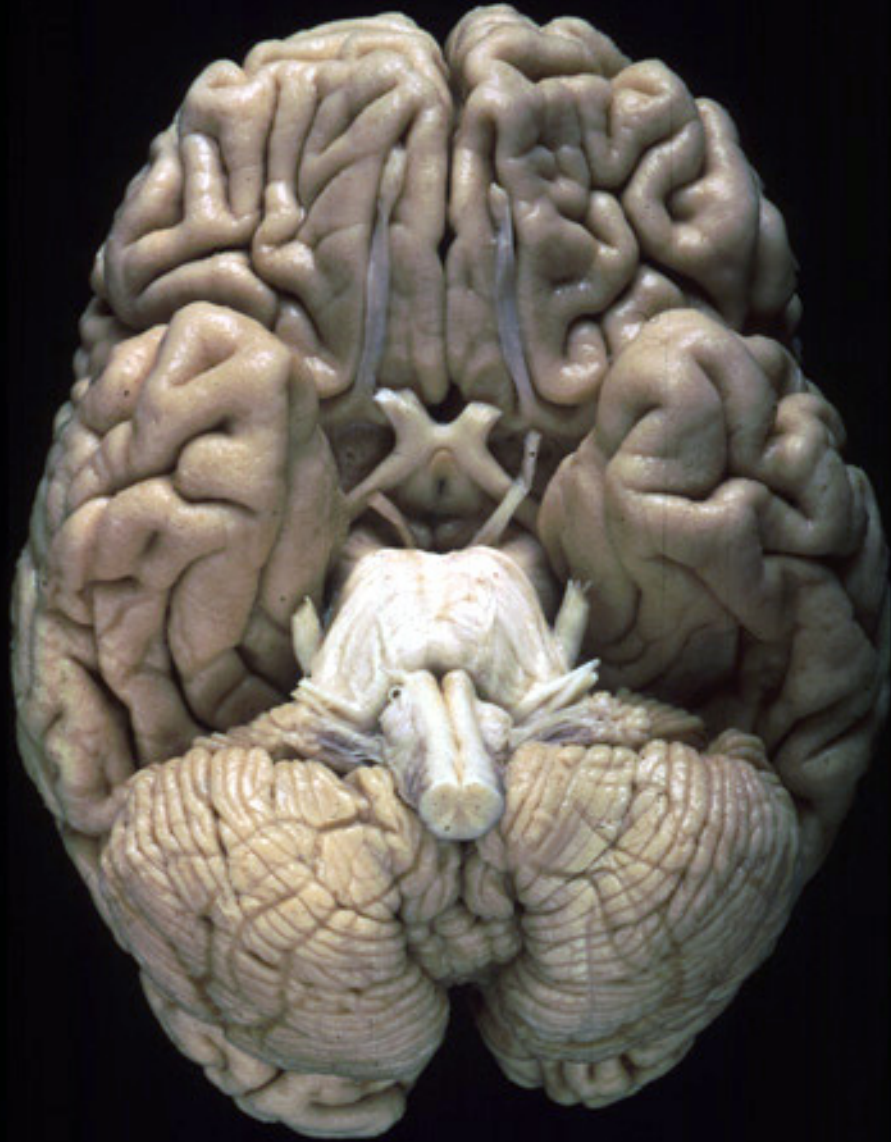

A hind thought?





Complex



“Little Brain”

- Largest structure in the posterior fossa
- Contains 50% of the brain's neurons due to its tiny granule cells; 10% of the brain's total weight
- Cozies up to the brain stem behind the pons, attached by the 3 white matter peduncles or “feet”:
 - superior, middle, and inferior peduncles

The overarching goal of the cerebellum, in conjunction with the basal ganglia, has always been considered to be refinement of motor output of the corticospinal and other descending motor systems via multiple feedback systems. However, the cerebellum and BG do not themselves project to LMN's directly.

At first glance...

Vermis (wormlike)

Vermis: control of the proximal and trunk muscles (posture, balance, gait)

Flocculonodular nodes (FN)

FN: vestibulo-ocular reflexes, eye movement and balance via vestibular system


Two large cerebellar hemispheres: (intermediate and lateral)

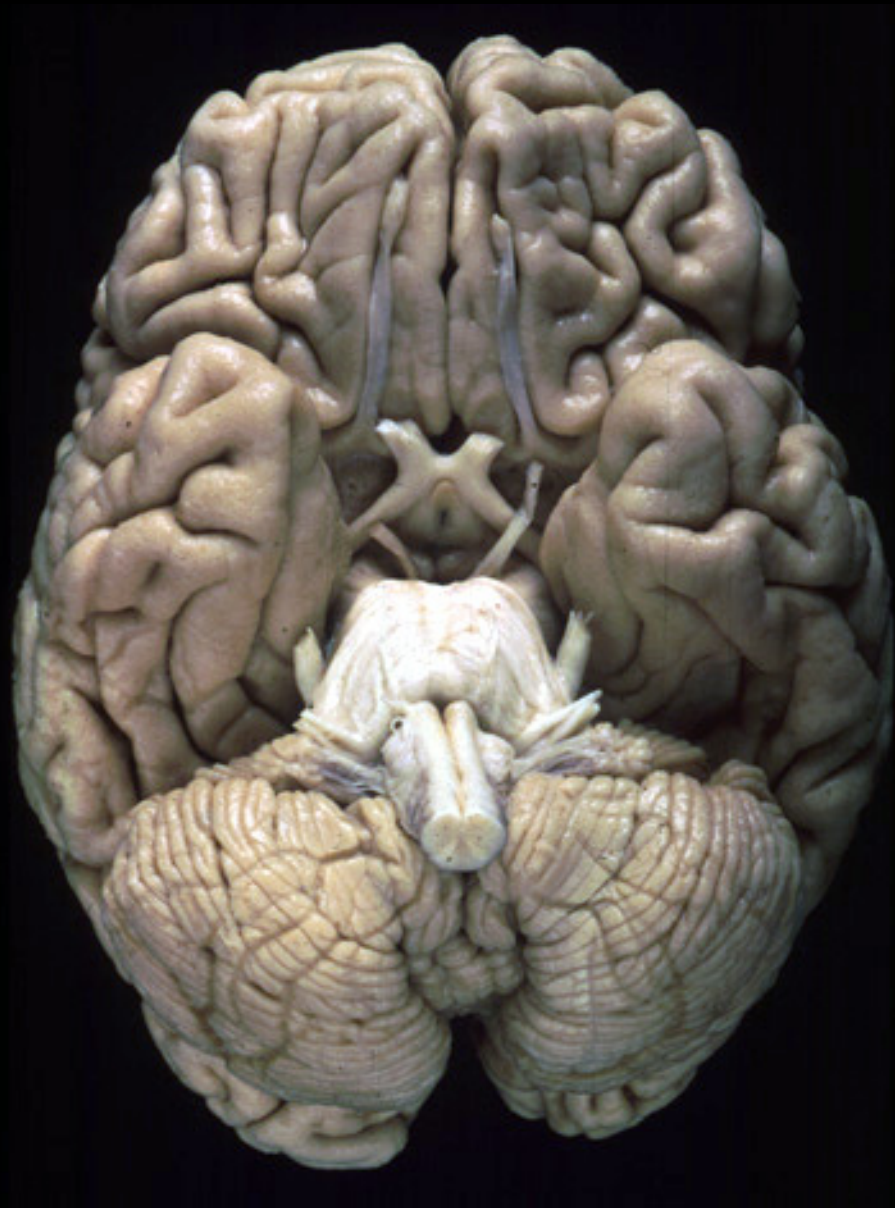Intermediate hemisphere: control of more distal appendicular muscles (arms/legs)

Lateral hemisphere (largest part): plans the motor program for the extremities; unilateral excision possible without severe deficits

Or “front to back” anatomically:

- Flocculonodular lobe
- Anterior lobe
- Posterior lobe





Feedback Loops

Motor cortex

Pons

Cerebellum

Thalamus


Cortex

Motor cortex

Basal Ganglia

Thalamus

Cortex



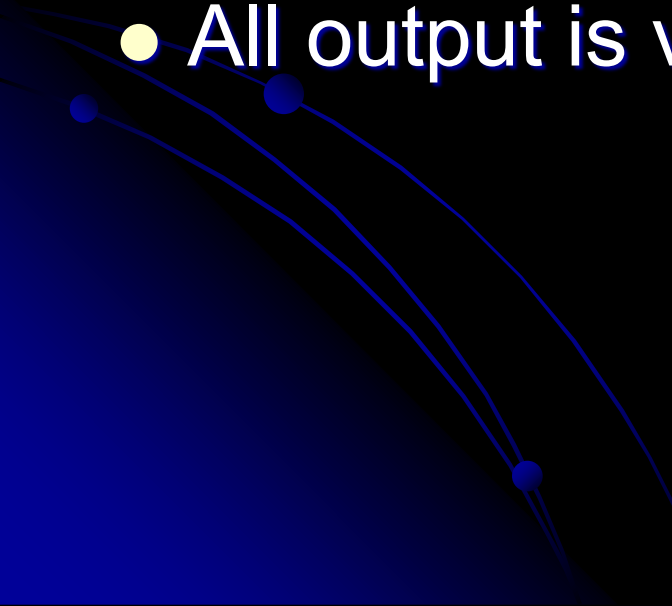
Input and Output

The cerebellum receives nearly 200 million input fibers (in contrast, optic nerve composed of 1 million)

Cerebellum and BG have major input from motor cortex; cerebellum has input from brainstem and spinal cord as well

Cerebellum and BG project back to the motor cortex via the thalamus

Ultimately...

- Virtually all input to the cerebellum is via the middle and inferior peduncles
 - All output is via the superior peduncle
- 

Superior Cerebellar Peduncle

Mostly efferent (from cerebellum)

Mostly originate from the dentate nucleus


Projection from SCP to mid brain structures including the red nucleus, ventral lateral/ventral anterior nucleus of the thalamus, and the medulla

Dentate > red nucleus > thalamus > premotor

Cerebellum > thalamus > premotor

Middle Cerebellar Peduncle

Entirely afferent fibers originating within the pontine nuclei as part of the cerebral cortex>pons>cerebellar tract.



Inferior Cerebellar Peduncle

Many types of input/output fibers

Main concern is integrating proprioceptive sensory input with motor vestibular functions such as balance and posture maintenance

- Proprioceptive information from the body is carried via the dorsal spinocerebellar tract to this peduncle and then the cerebellum


Within the Cerebellum

Most output from cerebellum originates with deep nuclei

Exception: the FN synapses directly on vestibular nuclei (VN) in the brainstem.

- VN are analogous structures to deep nuclei in that they receive both mossy fiber and Purkinje cell inputs.

Most input to the Deep Nuclei is via climbing
and mossy fibers of the cerebellum



Deep Nuclei

4 deep nuclei embedded in the white matter at the center of the cerebellum

Inhibitory (GABA) input via Purkinje cells in the cerebellar cortex

Excitatory (glutamatergic) input from mossy fiber and climbing fiber pathways

All output from the cerebellum is relayed by DN and VN

DEGF

“Don’t Eat Greasy Food”

Lateral to medial:

Dentate

Emboliform

Globose

Fastigial

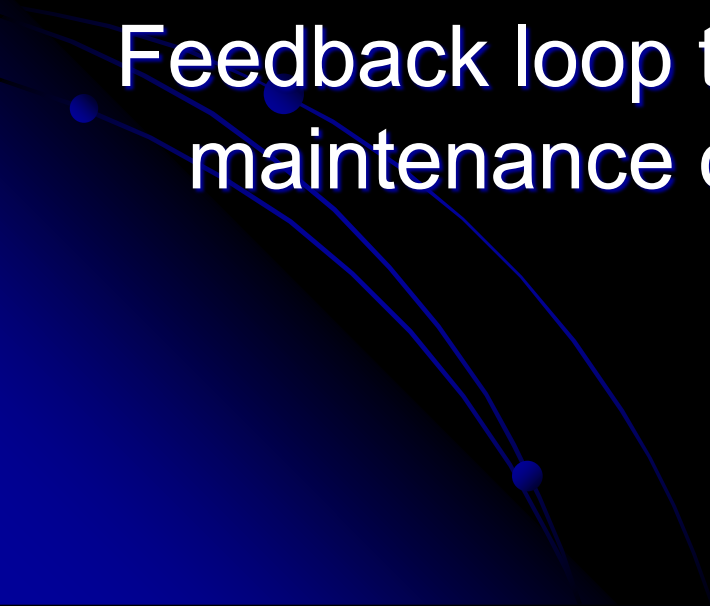
The Emboliform and Globose nuclei are called the “interposed nuclei”

Flocculonodular Lobes

Input: inferior and medial vestibular nuclei

Output: vestibular nuclei

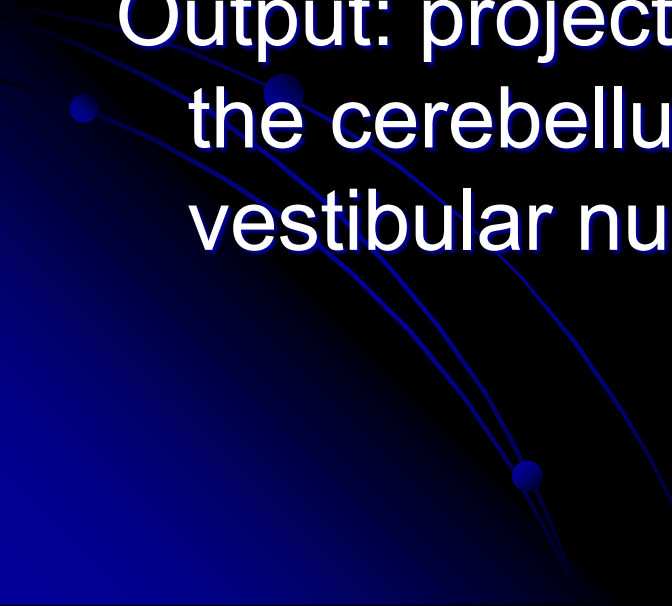
Feedback loop that allows for constant maintenance of balance



Vermis

Input: spinocerebellar tracts from the trunk of the body with information on position and balance of the torso

Output: projects to the fastigial nucleus of the cerebellum which in turn sends to the vestibular nuclei



Intermediate Lobe

Input: 1) corticopontocerebellar fibers originating in the motor cortex (duplicate info is sent from motor cortex to spine to effect movement)

2) Sensory feedback from muscles allowing comparison of what should happen with what is happening; activation during and in relation to movement

Output: Interposed nuclei

Lateral Lobe

Input: from the parietal cortex via pontocerebellar mossy fibers giving info on the location of the body in the world. Large #'s of feedback circuits allow for integration of body position information with indications of muscle position, strength, and speed

Output: Dentate nucleus

Blood Supply

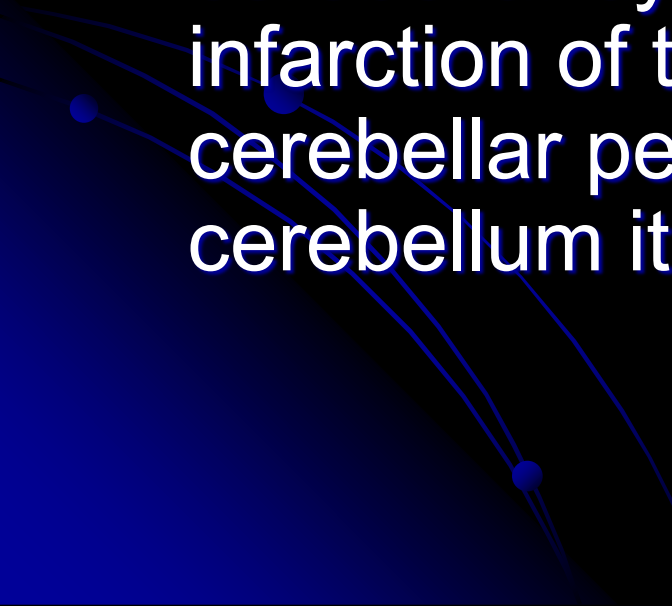
SCA=Superior cerebellar artery (basilar artery branch) supplies most of cerebellar cortex, nuclei, superior vermis, middle/superior cerebellar peduncles

AICA=Anterior inferior cerebellar artery (basilar artery branch) supplies to anterior portion of the inferior cerebellum, FN, as well as CN 7,8. Obstruction of AICA can cause paresis, paralysis, loss of sensation to the face, hearing impairment. Infarct at the cerebellopontine angle could cause hyperacusia (CN7) and vertigo (CN8)

PICA= posterior inferior cerebellar artery (vertebral artery branch) supplies posterior inferior cerebellum, inferior vermis, inferior cerebellar peduncle

Infarcts of the PICA and SCA are more common than the AICA.

Remember that many of the clinical sx of cerebellar dysfunction can result from infarction of the lateral medulla, pons, and cerebellar peduncles rather than the cerebellum itself



Infarcts causing unilateral (ipsilateral) ataxia with little to no brainstem signs are most commonly SCA territory.

Infarcts in the PICA or AICA most often involve the lateral brainstem in addition to the cerebellum

Large cerebellar infarcts of the PICA and SCA territories can cause edema of the cerebellum and 4th ventricle compression and thus hydrocephalus and brain stem compression.

- Hurley notes that 46% of cerebellar CVA pts who present as initially alert will deteriorate within 72 hrs.

Hemorrhage

Most often associated with HTN, AVM, post infarct, CA metastasis, etc. (see Blumenfeld)

Presenting sx incl: H/A, N/V, ataxia, nystagmus, impaired consciousness. Can present with N/V alone. Hemorrhage can be fatal.

Prompt ID and treatment yields “good functional outcome” typically

Cerebellar lesions typically produce ataxia, a “lack of order” between antagonistic and agonistic muscle movement

This produces classic irregular movement (overshoot, overcorrect)...

- As well as uncoordinated movement (poorly timed, ie “dysrhythmia,” or abnormal trajectory, ie “dysmetric”)

Ataxia

Acute Etiology

Intoxication: ETOH, Li,
AC
Post inf with inflam
Poisoning with mercury
or toluene
Post anoxia or
hyopthermic
CVA

Chronic Etiology

Chronic toxin exp
(ETOH)
Metastasis
MS
Degenerative D/O
Agenesis

Flavors of Ataxia

Truncal Ataxia results from vermis lesions yielding a wide based, drunk-like gait with few other significant abnormalities

Appendicular Ataxia results from lateral and intermediate injury yielding ataxia on movement of the extremities

More severe and lasting deficits are seen with lesions of intermediate lobes, vermis, deep nuclei and peduncles

Cerebellar connections in lateral motor systems are either ipsilateral or cross twice, thus ataxia in extremities is ipsilateral to the side of the lesion.

Also true for peduncles.

- Even with (medial) truncal ataxia, patients tend to fall or sway to the side of the lesion.

A note about ETOH

Alcohol abuse is a common cause of cerebellar lesions secondary to thiamine deficiency.

This typically affects degeneration of the anterior lobe such that a wide staggering gait is present but does not affect arm movement or speech.

Tests for Truncal Ataxia

Tandem gait

Romberg

Titubation (tremor of head or trunk)



Tests of Appendicular Ataxia

(Think: Dysmetria and dysrhythmia)

Finger-nose

Heel-shin

Finger to thumb crease rapid tapping

Intention tremor

Tapping hand with alternating palm/dorsum

Rapid double alternating movements

Abnormal Eye Movement

Occular Dysmetria: Saccades overshoot, undershoot target

Slow saccades or jerky intrusions in smooth pursuit eye movement (FN)

Nystagmus: horizontal and, less often, vertical

Suppression of the “vestibulo-ocular reflex”: thumb gaze fixation on trucal rotation yields nystagmus

“Ocular flutter” refers to brief bursts of oscillating movement during fixation

Other Problems

Scanning or explosive speech (rate/volume irregularities)

Slurred speech (think ETOH)


AND...



Cerebellar Cognitive Affective Syndrome (CCAS)

Defined in the “Companion to Clinical Neurology” (Pryse-Phillips, 2003) as:

“Behavioral changes occurring in pts with lesions involving the posterior lobe of the cerebellum and the vermis, characterized by impairment of executive functions...”



Such As:

Planning

Set shifting

Verbal fluency

Abstract reasoning

Working memory




Difficulty with spatial cognition

Such as:

V/S organization

V/S memory

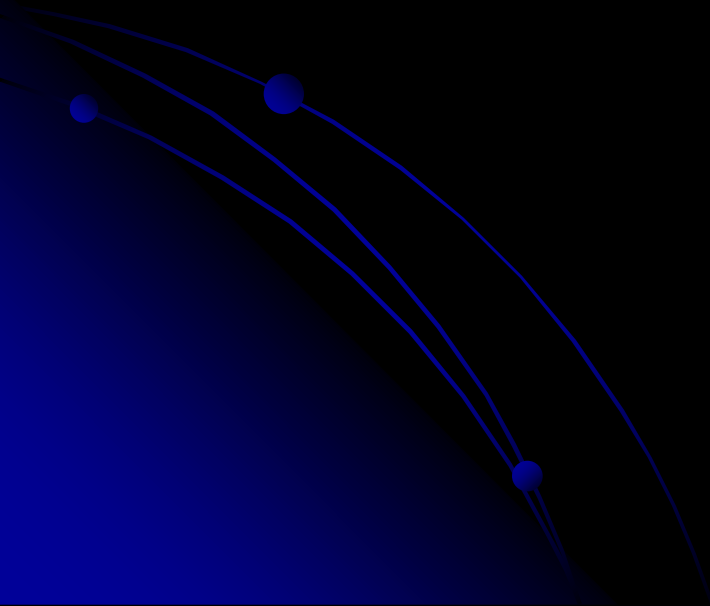


Personality Changes

Such as:

Blunting of affect

Disinhibited and inappropriate behavior

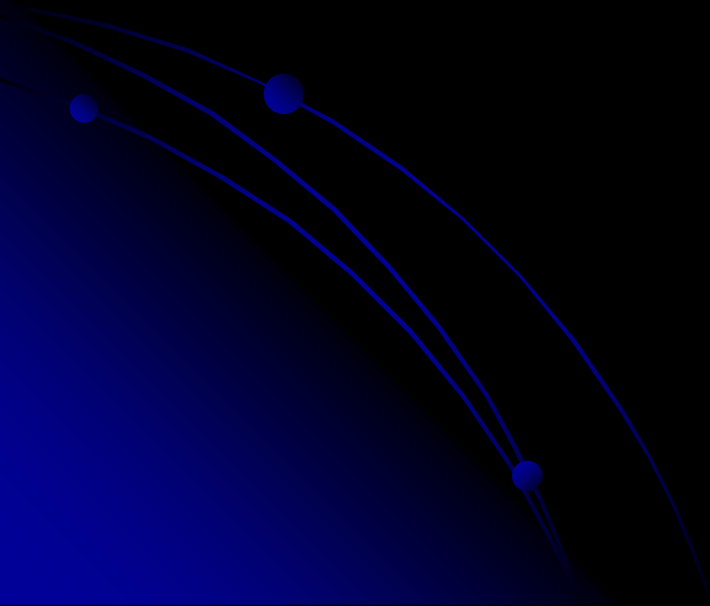


Language Deficits

Such as:

Agrammatism

Dysprosodia



Pryse-Phillips adds:

“Lesions of the anterior lobe of the cerebellum produce only minor changes in executive and V/S functions.

The constellation of deficits is suggestive of disruption of the cerebellar modulation of neural circuits that link prefrontal, posterior parietal, superior temporal, and limbic cortices with the cerebellum.”

Per Schmahmann...

A broader view of cerebellar impairment should include a “universal dysmetria” of movement, thought and emotion.

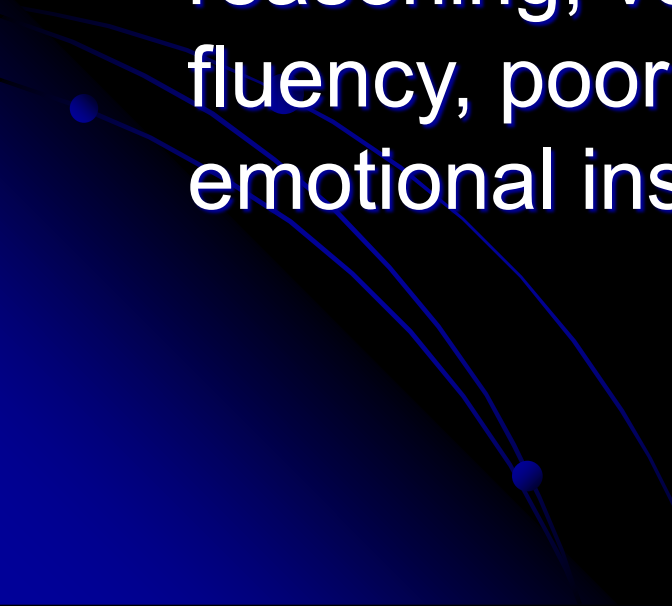
CCAS includes impairment in executive, v/s and linguistic abilities and...

- Affective disturbance, ranging from emotional blunting and depression to disinhibition and psychotic features.

Roots for an Expanded Cerebellar Role in Cognition and Affect

- Reports throughout the 1800's described pts with different forms of cerebellar damage including intellectual, emotional and psychiatric dysfunction.
- Later studies in schizophrenia linked psychosis with a smaller cerebellar vermis and cerebellar atrophy
- 20th c. studies found pts with olivopontocerebellar atrophy had problems with verbal intellect, v/s ability, learning and memory, and frontal systems including strategy formation and procedural learning.

Genetic diagnosis of spinocerebellar ataxia (SCA) into distinct categories also reveals findings of impaired executive function including verbal fluency and conceptual reasoning, verbal STM deficits, verbal fluency, poor motor set shift (Luria), and emotional instability and impulsivity.




Focal cerebellar lesion studies have found problems with agrammatism, decreased verbal fluency, and inability to detect own errors in verb for noun generation paradigm. There are difficulties in ataxic pts with attentional modulation, motor skill learning, and ability to acquire conditional associative reflexes.

Schmahmann led a study funded in part by NIMH grant studying 20 pts with lesions confined to the cerebellum (13 CVA, 3 postinfectious cerebellitis, 3 cortical atrophy, 1 midline tumor)

- Evaluated with neurological exam, bedside tests, neuropsych testing identifying:

Deficits in

- Planning
 - Set shifting
 - Abstract reasoning
 - WM
 - Verbal fluency
- 

- Vis Spatial disorganization
- Visual memory

- Blunted affect
- Disinhibited/inappropriate behavior

- Dysprosodia
- Agrammatism
- Mild anomia

Net effect was a general lowering of overall intellectual function

Deficits were more pronounced and generalized in those with bilateral or large unilateral infarctions in the posterior lobes in the territory of the PICA and in those with subacute onset pancerebellar disorder

The vermis was consistently involved in patients with pronounced affective presentations

Less pronounced in more slowly progressive degenerative conditions and those 3-4 mo post CVA or with small SCA lesions.

Other Studies

- Work by Malm et al (Neurology, 1998) demonstrated deficits in attention, WM, V/S, and cognitive flexibility
- Studies by Neau (Acta Neurol Scand, 2000) and others showed deficits in EF, spatial cognition, attention, and some language tasks
- Single case reports have shown pts with right cerebellar infarct develop impairments of linguistic processing including agrammatism and decreased verbal fluency.

Kaufer presented cases vignettes of cerebellar conditions with associated emotional and cognitive changes, some difficult to distinguish from FTD or Frontal AD variants

Hurley observed pubmed citations:

Cerebellum + cognition= 620

Cerebellum + mood=136

Cerebellum + psychosis=109

Functional imaging studies beginning mid to late 1980's have shown the cerebellum is activated by a lg # of cognitive tasks devoid of movement (memory, language, etc) but were generally considered "incidental" findings.

PET studies in normals showed activation of cerebellar hemispheres with emotional films.

Generalized atrophy found in major depressive disorder, Bipolar Mood Disorder

V3 smaller in multi episode Bipolar pts

Increased vermal blood flow and decreased cerebellar flow on treatment of depression

Proposed cerebrocerebellar circuit

Feedforward: Cortex > pontine nuclei > cerebellar cortex > red nucleus > thalamus > cortex

(Schmahmann, 1991, 1994, 1996, 1997)

Feedback: DN > thalamus > motor cortex > posterior parietal > superior temporal > prefrontal > SMA > cingulate > parahippocampus

Behaviorally Defined Disorders with Cerebellar Anomalies

Autism (Bauman & Kemper, 1997)

Schizophrenia (Levitt, 1999; Nopoulos, 1991;
Loeber, 2001)

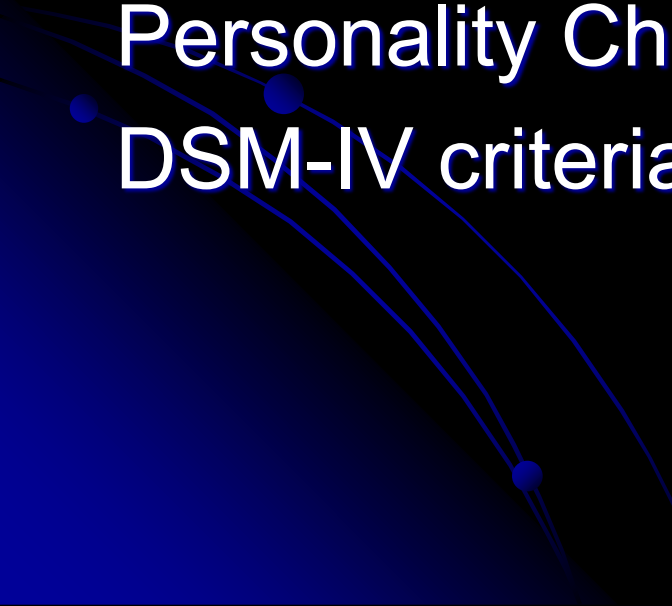
ADHD (Berquin, 1998; Mostofsky, 1998;
Castellanos, 2001)

Dyslexia (Nicolson, 1999)

Pre-term infants (Allin, 2001)


A study of degenerative cerebellar disease
by Leroi, 2002 (n=31) found:

Non-cognitive psychiatric d/o	77%
Mood disorder	68%
Personality Change	26%
DSM-IV criteria for dementia	19%



Schmahmann cites numerous other “confirmatory studies” supporting CCAS in cerebellar dysfunction.

Adding to Hurley’s imaging review, he summarized that cerebellar activation as part of functional imaging studies has identified in association with:



Sensorimotor activation

Sensory processing and discrimination

Mental imagery

Classical conditioning

Nonmotor learning and memory

Linguistic processing, including Braille

Attentional modulation

Timing estimation

Emotion perception and experience

Visual spatial memory

Executive function

Autonomic function (pain, thirst, hunger, smell, hypoxemia)

Proposed CCAS Anterior-Posterior Functional Schema

Sensorimotor:

predominantly anterior lobe (I-V)

secondarily represent (VIII, IX)

Cognitive, Affective:

vermal and hemispheric components
(VI, VII)



Proposed CCAS Medial-lateral Functional Schema

Vermis and fastigial nucleus:

autonomic reg, affect, emotionally
important memory

Cerebellar hemispheres and dentate nucleus:

executive, v/s, linguistic, learning and
memory



Schmahmann's Bottom Line

“Need to Know”

Therapy and rehab needs

Psychopharm investigation and treatment

Potential for future therapeutic interventions,
ie. cerebellar deep brain stimulation?



Case Study

- 50 yr old RH male referred to NP assessment by neurologist
- “Left cerebellar stroke” with residual complaints of decreased balance, dexterity, dizziness, H/A, poor memory, confusion and fatigue
- CVA onset after chiropractic maneuver, immediate visual blurring, unable to sit due to truncal ataxia

- CT and MR angiogram at time were unremarkable
- 2 months later identification of a small area of encephalomalacic change in left cerebellar hemisphere. No evidence of vertebral dissection. Echocardiogram WNL
- Repeat imaging 9 mos later again showed 9mm lacune in the inferior portion of the left cerebellum with some encephalomalacic change posterior to this within the inferior portion of the left cerebellum and extending superiorly. No interval changes

MRA revealed 75-80% stenosis at bifurcation of the basilar artery at origin of right PICA and 60% stenosis at the origin of the left PICA. Stenosis was not present at original imaging.

MRI cervical spine showed focal right paracentral protrusion at C4-5, broad based disk bulge at C5-7. EMG consistent with C5-6 radiculopathy.

- Original headaches in nucho-occipital region and bifrontal
- Later complaints in right retro-orbital, bilateral temporal areas; subsequently left sided.
- Daily H/A's since CVA, sometimes 2-3/d, worsened by sleep deprivation. C/o fatigue
- Sleep apnea suspected, later ID'd.
- Remained ataxic, worse on rising
- Endorsed odd sensations, "Like my brain waves don't connect" worsened by exertion or bending; 2-30sec duration

- Onset of depression following CVA with little prior hx although employment/functional limitations impacted mood
- New onset generalized anxiety with “instant” anger but no awareness of intense emotion. GF says, “He’s very flat now.” Forgets her BD; no sentimentality
- No significant ETOH or S/A hx since teens but now smokes some marijuana (“one hit every other day for H/As”)
- New olfactory complaints of “always smelling something burning”, no A/V hallucination
- Sense of being detached from self after CVA as if “unconnected”; increased déjà vu.
- Unexplained gaps in time. GF says “He checks out but will respond”

- Developmental hx supportive of ADHD, not aware of significant perinatal or childhood trauma, no developmental delays in talking, walking, enuresis
- GED, report of slow to read, poor spelling, poor reading comprehension
- Employment hx as carpenter and casino manager (200 employees).

NP Findings

- MMSE: 29/30 (3 stage); World OK but poor serial 7's
- IQ: Receptive vocab average range, expressive in low average range; WASI was in average range (even profile).

- Memory: LA-avg recall with more difficulty on ROCFT (copy organization OK, many minor inaccuracies)
- V/S: line orientation was MI, BD was average, HVOT mildly impaired
- Attention: LA WM, variable LA-HA simple attn., SymS was LA.
- Language: LA naming (more difficult item errors), MI-LA phonemic fluency; semantic fluency avg. Narrative writing sample poor (3 run ons, article omissions, punct errors, capitalization and tense errors)
- EF in avg to high average range but more difficulty shifting set and novel problems solving.

- SI on motor speed and fine motor skills bilaterally. Left hand more dysmetric. Luria poor. Left sided vis/tactile imperception errors. Double alt movements were slow, dysmetric, jerky. Romberg positive. Couldn't do stressed gaits. Finger nose dysmetric.
- Mood moderately depressed, mild to mod anxiety

Discussion:

What extent does ADHD, OSA, marijuana use impact profile?

What recommendations would you have made for further diagnostic value?

What therapeutic interventions would you recommend?

