

We present a case of Rasmussen's encephalitis that illustrates the developmental, medical, cognitive, and social aspects of this devastating progressive condition over time.

The patient is a 25 year old right-handed woman who developed right hemisphere complex partial seizures at age 8. Following EEG telemetry, neuropsychological evaluation, imaging and a Wada test revealing left hemisphere speech, she underwent a right frontal lobectomy at age 9, sparing the temporal lobe as well as motor cortex. Left upper extremity motor skills at the time were normal. Pathology was consistent with Rasmussen's encephalitis. Since then, her seizures have never been completely controlled despite multiple medications and participation in drug trials. Further neurosurgery (functional hemispherectomy) has been offered on several occasions, but the patient and family have not to date elected this intervention. Serial MRI scans show diffuse volume loss throughout the remaining right hemisphere, including the hippocampal formation.

Follow-up neuropsychological evaluations were conducted when the patient was 10, 13, 18 and 25. Although the patient has grown cognitively since age 8 and acquired some new skills, her intellectual scores relative to peers have declined from Verbal IQ at the 94th percentile and Performance IQ at the 70th percentile at age 8, to VIQ at the 10th percentile and PIQ at the 4th percentile at age 25. Her visual memory scores deteriorated before her verbal memory scores, now both in the borderline range. Left-hand motor abilities and sensory perceptual skills deteriorated significantly by age 18, and now she holds her left hand in a contracted posture. Problems with social inappropriateness, nonexistent prior to seizure onset, became apparent as the patient entered her teenage years. She graduated from high school but is not working and still lives with her parents. Issues with psychogenic nonepileptic spells in addition to epileptic seizures have been documented. Medical maintenance and counseling efforts with the patient and her family continue.

Initially, the patient presented as a bright, normal and socially outgoing child; she excelled in her third grade classroom, had many friends, and scored above average intellectually. Following her right frontal lobectomy, with continuing seizures and higher doses of antiepileptic medications she continued to learn but her standardized test scores (intellectual, memory, academic) declined significantly in comparison to peers.

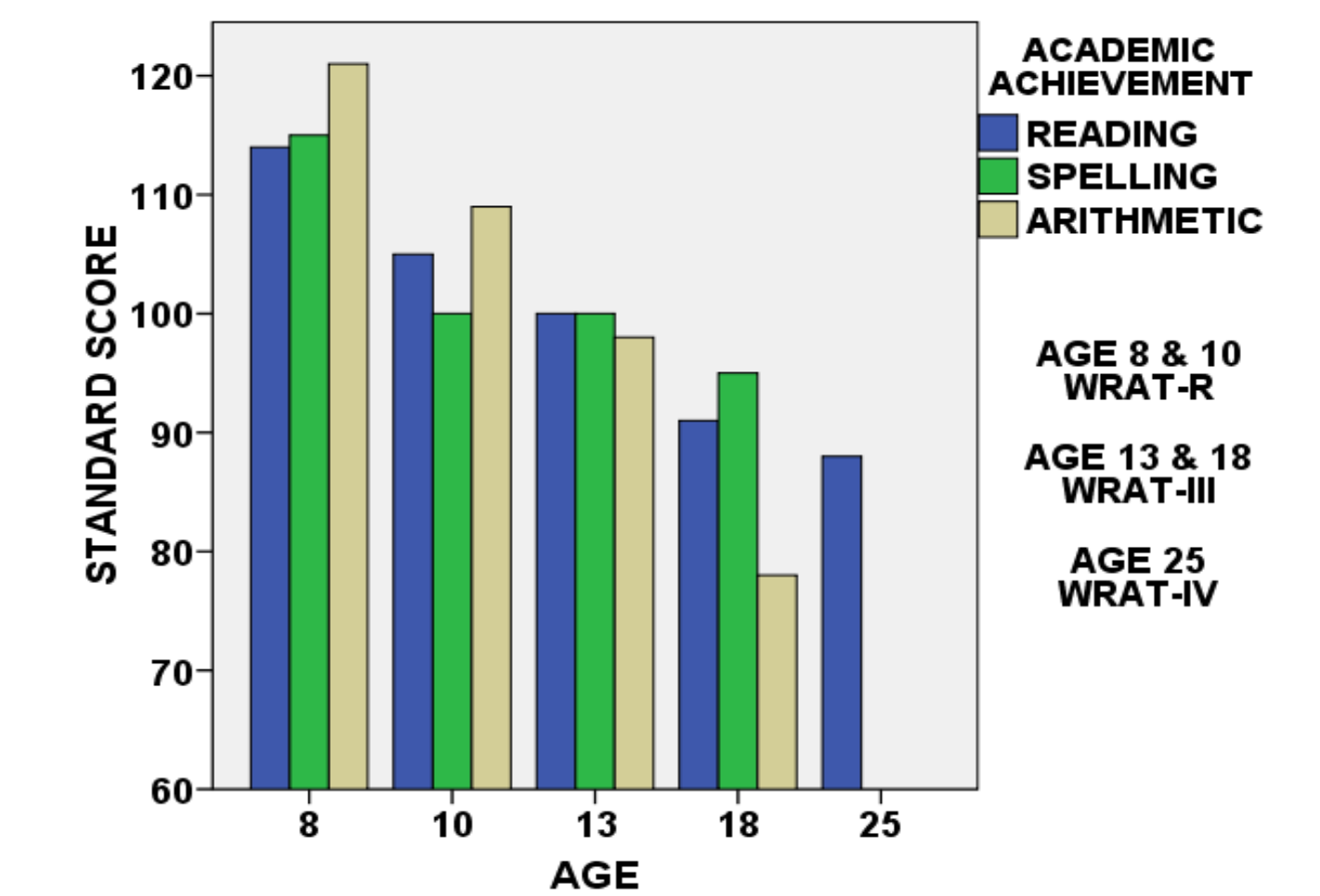
The palliative right frontal lobectomy at age 9 did not result in reduction of seizures. The patient's most recent EEG monitoring showed complex partial seizures beginning with aura, progressing to head-turning to the left, mouth-twitching, left-extremity shaking and unresponsiveness, sometimes with Todd's paralysis. Seizures occurred 3-5 times per week. Documented psychogenic seizures also occurred periodically during her adolescence and young adulthood, but diminished with reassurance and patient/family education. She continues to be treated with multiple medications, and many combinations (including in drug trials) have been tried over the years.

Neuropsychological batteries included age-appropriate measures of intellectual level (Wechsler Intelligence Scale for Children-Revised and Wechsler Adult Intelligence Scale-III), memory (Wide Range Assessment of Memory & Learning and Wechsler Memory Scale-III), academic achievement (Wide Range Achievement Test-Revised, -III & -IV), attention, language, sensory perception, motor speed and strength, visual-motor functioning, sequencing, and executive functioning. Selected measures are presented here. Psychosocial inventories completed in the first four evaluations yielded normal profiles. Her last testing was discontinued due to a seizure, and therefore did not include inventories.

Prior to surgery the patient demonstrated better verbal than visual-spatial skills on her intellectual examination, a pattern that has continued over time. Nonverbal IQ scores decreased more quickly than verbal scores. Post-operative memory scores also declined over time, with nonverbal scores decreasing sooner.

Commensurate declines in academic achievement scores were also documented. Arithmetic skills peaked at the 7th grade level at age 13 and decreased to 5th grade level at 18. Single-word reading and spelling skills were maintained at 8th grade level. The patient attended a private Christian school without a special education program, but graduated with accommodations and modifications to the standard curriculum. With her heavy medication load, she slept every afternoon after school and worked for hours on homework in the evenings, thus precluding her participation in after-school social activities.

Over time, the patient's left hand motor skills declined, both relative to increasing right-hand measures and to previous left-hand skills. Due to a right-hand injury suffered during a seizure, she declined to participate in most motor tasks in the recent testing. Her surgery at age 9 was limited to spare her normal left hand functions, but her physicians now predict that functional hemispherectomy would result in little further loss of motor functions. She now experiences frequent twitches of the left upper extremity. The beginnings of a left visual field deficit were documented in the recent testing.

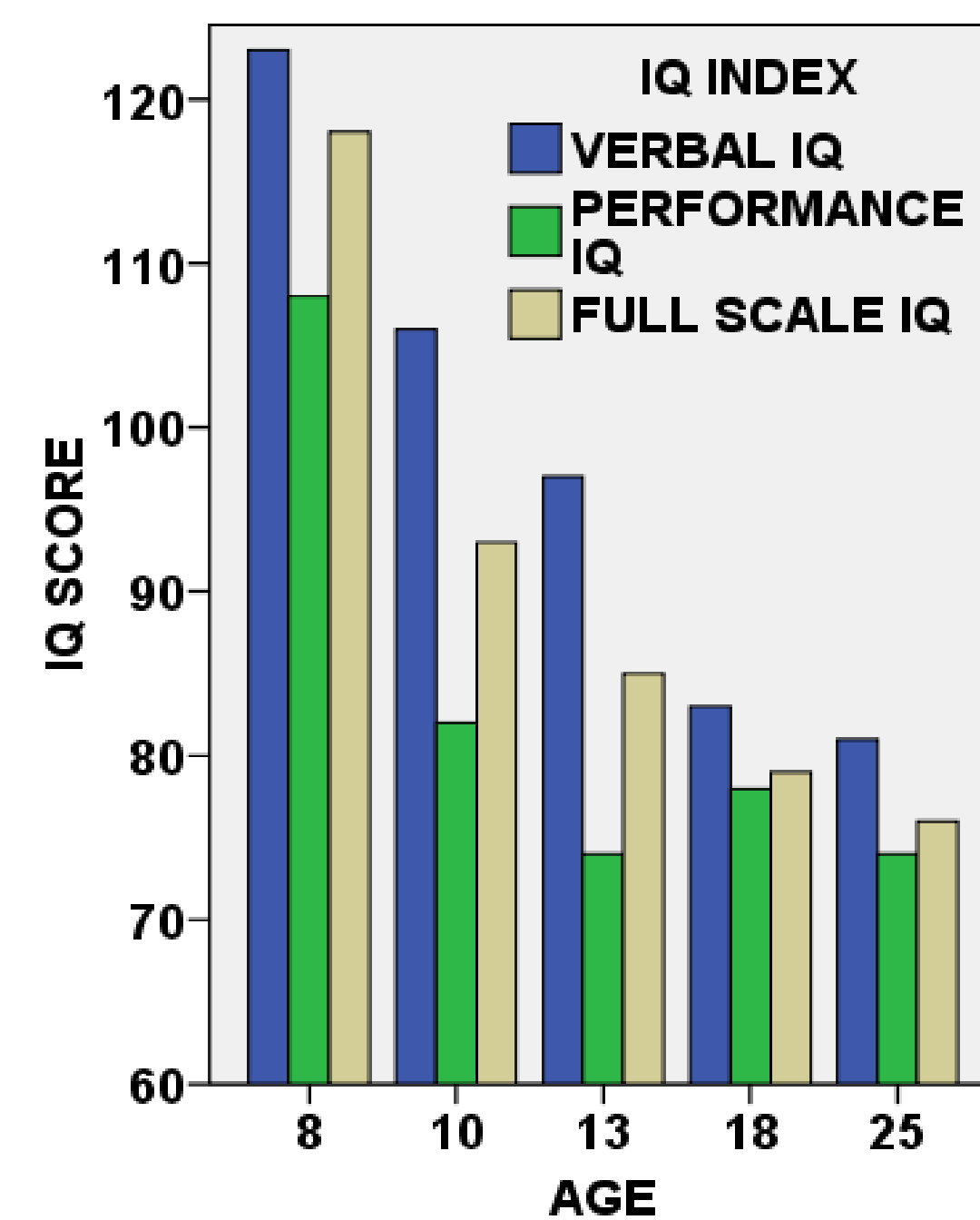
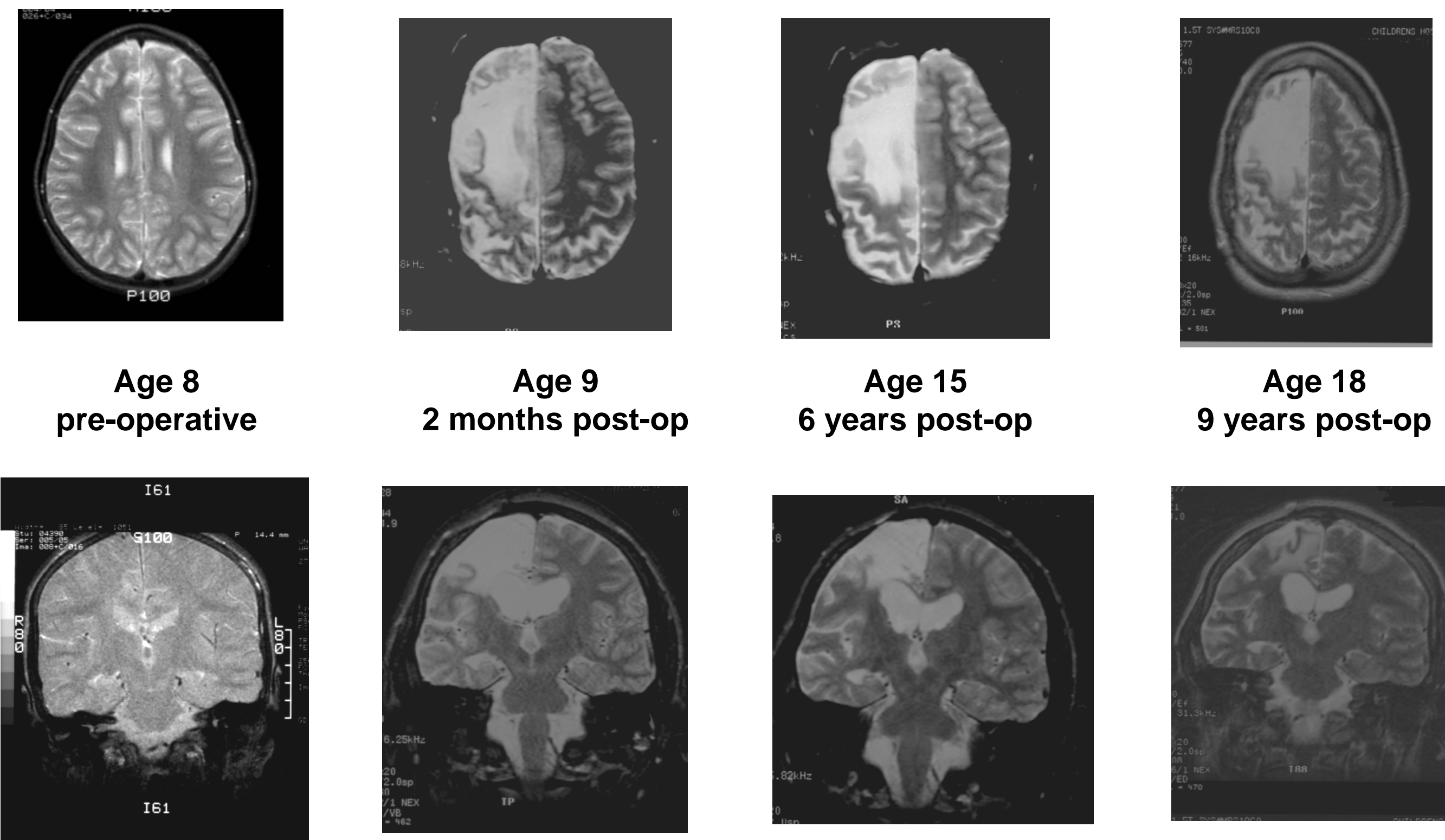


After her surgery the patient lost her musical talents. In her teenage years she often spoke inappropriately loudly, and social judgment issues emerged. Her peers began to shun her, and she found companionship with younger children and with adults.

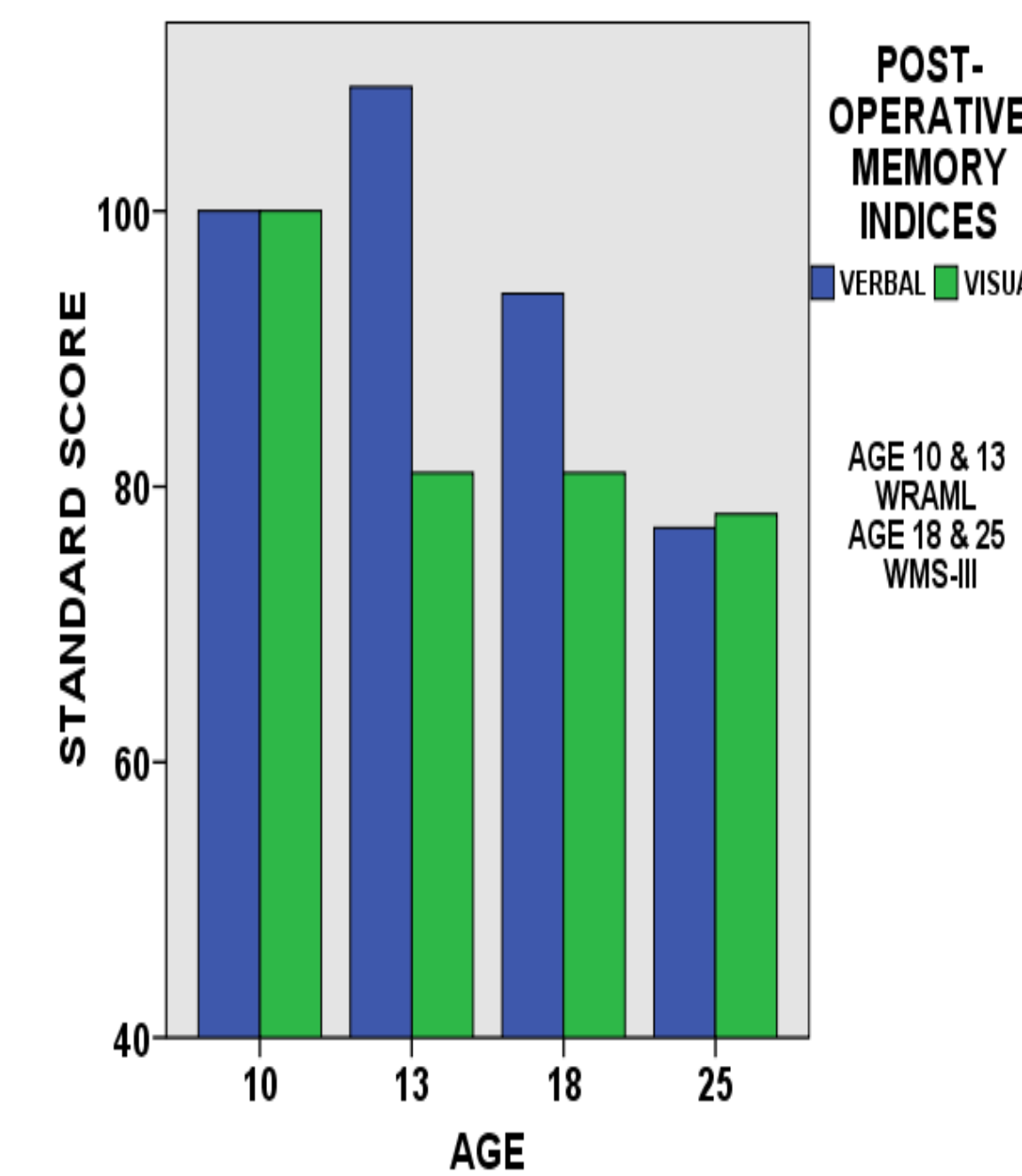
Following her graduation the patient briefly attended a vocational program. She left her only job after two months due to seizures, and has not worked since. The family has chosen to emphasize safety and protection over efforts to develop independence, and they plan for her to live with parents for the foreseeable future.

Functional hemispherectomy, a drastic intervention for a devastating progressive disease, is usually an elective procedure. Our patient and her family have not thus far elected to pursue this possible cure for her seizures, a decision that we professionals in the epilepsy surgery field must respect.

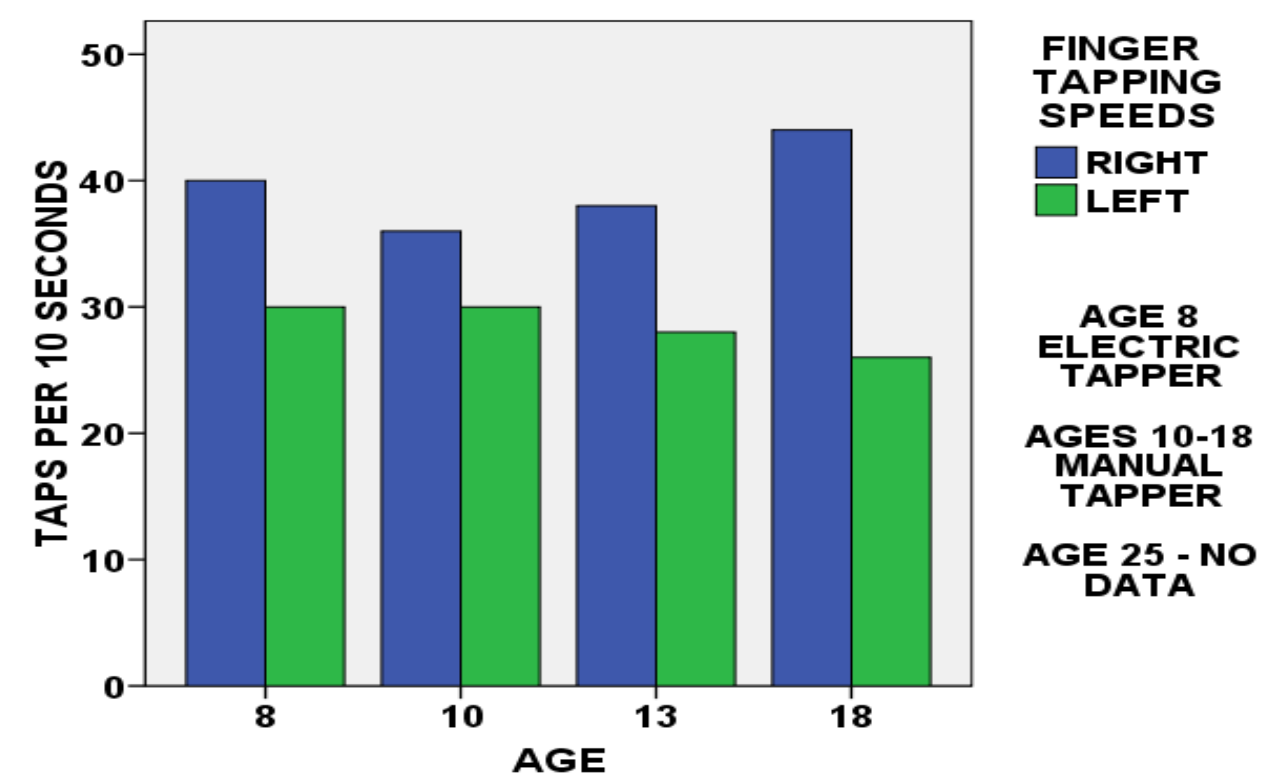
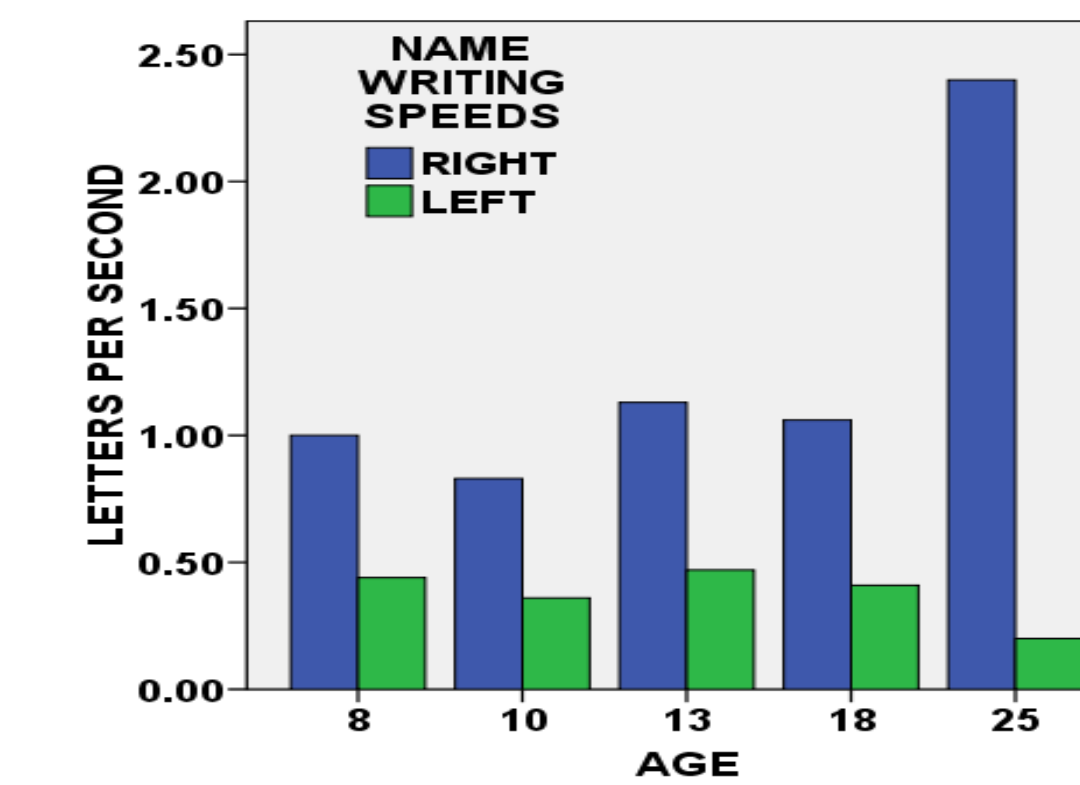
If you were in the position of having to make these very difficult choices for yourself or for your child, what would you decide to do?



AGE 8, 10 & 13 - WISC-R
AGE 18 & 25 WAIS-III



AGE 10 & 13 WRAML
AGE 18 & 25 WMS-III



AGE 8 ELECTRIC TAPPER
AGES 10-18 MANUAL TAPPER
AGE 25 - NO DATA